

# *Thoracolumbar imbalance analysis for osteotomy planification using a new method: FBI technique*

*J. C. Le Huec, P. Leijssen, M. Duarte & S. Aunoble*

**European Spine Journal**

ISSN 0940-6719

Eur Spine J

DOI 10.1007/s00586-011-1935-  
y



**Your article is protected by copyright and all rights are held exclusively by Springer-Verlag. This e-offprint is for personal use only and shall not be self-archived in electronic repositories. If you wish to self-archive your work, please use the accepted author's version for posting to your own website or your institution's repository. You may further deposit the accepted author's version on a funder's repository at a funder's request, provided it is not made publicly available until 12 months after publication.**

## Thoracolumbar imbalance analysis for osteotomy planification using a new method: FBI technique

J. C. Le Huec · P. Leijssen · M. Duarte · S. Aunoble

Received: 11 July 2011 / Accepted: 11 July 2011  
© Springer-Verlag 2011

### Abstract

**Introduction** Treatment of spine imbalance by posterior osteotomy is a valuable technique. Several surgical techniques have been developed and proposed to redress the vertebral column in harmonious kyphosis in order to recreate correct sagittal alignment. Although surgical techniques proved to be adequate, preoperative planning still is mediocre. Multiple suggestions have been proposed, from cutting tracing paper to ingenious mathematical formulas and computerised models. The analysis of the pelvic parameters to try to recover the initial shape of the spine before the spine imbalance occurred is very important to avoid mistakes during the osteotomy planification.

**Material and method** The authors proposed their method for the osteotomy planning paying attention to the pelvic, and spine parameters and in accordance with Roussouly's classification. The pre operative planning is based on a full-body X-ray including the spine from C1 to the femoral head and the first 10 cm of the femur shaft. Using all the balance parameters provided, a formula name FBI is proposed. Calculation of the osteotomy is basic goniometry, the midpoint of the C7 inferior plateau (point a) is transposed horizontally on the projected future C7 plumb line (point b) crossing posterior S1 plateau on a sagittal X-ray. These are the first two reference points. A third reference point is made on the anterior wall of the selected vertebra for osteotomy at mid height of the pedicle (point c) mainly L4 vertebra. These three points form a triangle with the tip being the third reference point. The angle represented by this triangle is the theoretical angle of the osteotomy. Two

more angles should be measured and eventually added. The femur angulation measured as the inclination of the femoral axis to the vertical. And a third angle named the compensatory pelvic tilt to integrate the type of pelvis. If the pelvic tilt is between 15 and 25° or is higher than 25° you must add 5 or 10°, respectively. This compensatory tilt is based on a clinical analysis of operated patients.

**Results** This planification was applied in a retrospective study of 18 patients and showed why in some cases improper correction was performed and prospectively in 8 cases with good clinical outcomes and correct spinal alignment. Sometimes it is necessary to find an acceptable compromise when rebalancing the spine paying attention to the general parameters of the patients like: age, osteoporosis, systemic disease etc.

**Conclusion** This FBI technique can be used even for small lordosis restoration: it gave a good evaluation of the amount of correction needed and then the surgeon had the choice to use the appropriate technique to obtain a good balance.

**Keywords** Spinal imbalance · Posterior wedge osteotomy · Subtraction osteotomy · Calculation method · Clinical outcomes

### Introduction

In order to be able to stand and walk in an upright position, humans have developed a specific spine–pelvic relationship. The sagittal equilibrium depends on a fragile balance between spinal curvatures, pelvic shape and position of the lower limbs [24]. C7 plumb line is the main concept for balance calculation. Anterior imbalance occurs as the plumb line of the 7th cervical vertebra passes in front of the femoral heads [23].

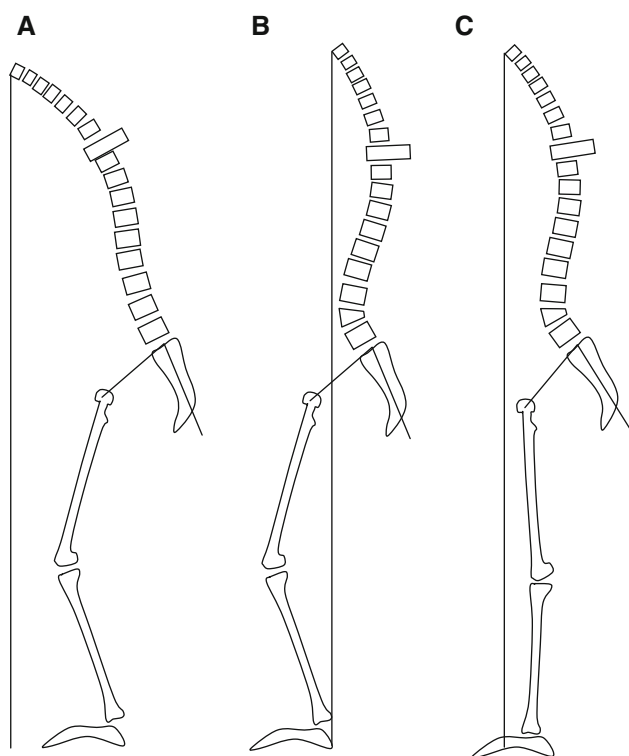
J. C. Le Huec (✉) · P. Leijssen · M. Duarte · S. Aunoble  
Spine Unit 2, Surgical Research Lab, Bordeaux University  
Hospital, CHU Pellegrin, 33076 Bordeaux, France  
e-mail: j-c.lehuec@u-bordeaux2.fr

Aetiology is iatrogenic [26] such as insufficient imposition of lordosis when performing arthrodesis, insufficient reduction of severe spondylolisthetic deformities and failure to perform an instrumented stabilisation in extensive laminectomies [6, 7, 13, 16, 17, 28].

Some thoraco-lumbar spinal pathology such as ankylosing spondylitis [8], spinal stenosis with kyphosis [6], scoliosis [11], etc. have a higher rate of sagittal imbalance [14, 30].

Initial compensation is by actively increasing lumbar lordosis if muscle power is sufficient and if additional extension of the lumbar spine is still possible [28]. Tilting the pelvis backwards adds further compensation. As hip extension reaches its limits, pelvic tilting can be obtained by flexing the knee joints (Fig. 1a). Effectiveness of orthopaedic treatment such as physiotherapy and orthotics devices is very limited [19, 20].

A spinal osteotomy is a possible treatment option to restore trunk balance [3–5, 10, 12]. Several surgical techniques have been developed and proposed to redress the vertebral column in order to recreate correct sagittal alignment. The most common are: Smith-Peterson [5], opening- and closing wedge osteotomies [21, 25], they all provide augmentation of lumbar lordosis or try to diminish thoracic kyphosis.



**Fig. 1** **a** Typical position with femur–knee flexion attempting to counteract kyphosis. **b** OST L4 corrects lack of lumbar lordosis but is insufficient because femur is still in flexion. **c** If femur is vertical the correction is insufficient. Pelvic incidence is equal for **a**, **b** and **c**

Osteotomies have demonstrated high efficacy in many papers but the pre-op planning is often unclear in the literature [3–5, 10, 12], leading to inappropriate correction (Fig. 1b, c)

Multiple suggestions have been proposed, from cutting tracing paper to ingenious mathematical formulas [22, 29] and computerised models [1]. Recently, Leijssen and Le Huec [19] proposed a simple and efficient method to approximate the amount of correction needed with a pre op evaluation of the desired C7 plumb line position postoperatively.

The strategy to correct sagittal imbalance depends on the origin of the sagittal imbalance and on the amount of correction requested. There are three common situations for the origin on the sagittal imbalance:

1. Localized angular kyphosis due to fracture, previous surgery, tumors, where the correction should focus on the level of the angular deformity using if needed posterior subtraction osteotomy (PSO) or vertebral corpectomy resection (VCR) with restoration of anterior column height.
2. Flexible harmonious kyphosis where the deformity is primarily disc-based. To improve sagittal balance the anterior column can be reconstructed through an anterior or posterior approach using bone graft or interbody cages. Polysegmental interpedicular osteotomies are used for a posteriorly based correction. In many cases this polysegmental correction is sufficient
3. Fixed global kyphosis deformity like ankylosing spondylitis or post long surgical fusion, where the technique is determined by the degree of correction required and is often a combination of osteotomies like PSO or VCR and segmental corrections

The authors present their experience for severe imbalance correction in the past 10 years using variable osteotomies technique on a retrospective series of 18 patients and propose a strategy for pre-operative planning according to pelvic parameters and spine stiffness with a more recent prospective series showing the efficiency of the strategy adopted named FBI for full balance integrated. Posttraumatic localised angular kyphosis is excluded.

## Material and method

The FBI technique is based on a global analysis of the full body balance

The amount of correction requested is based on geometric calculation using appropriate X-ray measurement. Full spine imaging from C1 to pelvis including the hips and femurs on Long X-ray films are requested. This is a common X-ray digitalized acquisition or this can be obtained

with the EOS system (Biospace, France) [9]. The EOS is a new, low-dose radiation, X-ray system providing full body images in standing position including head and lower limb.

Thoracic kyphosis and lumbar lordosis are determined by Cobb angle measure. Standard pelvic parameters such as pelvic incidence (PI), pelvic tilt (PT) and sacral slope (SS) are registered [18]. To determine the amount of correction requested the FBI (full balance integrated) technique used three angle measurements:

- Angle of C7 translation (C7TA): The lumbar lordosis in imbalance cases is always very low or even negative. The restoration of the lumbar lordosis is the common method to re-establish the balance as shown by Debarge [8]. The apex of the lumbar lordosis in a normal population is always located around L4 vertebra [24]. For this reason the calculation of the correction requested is basic goniometry using L4 vertebra as a reference point (c). To restore a good balance it is admitted that C7 plumb line should pass through the S1 plateau [11, 28]. To restore a good balance the midpoint of the C7 inferior plateau (point a) is transposed horizontally on the projected future C7 plumb line (point b, the ideal position for C7) passing through S1 plateau on a sagittal standing X-ray (Fig. 7). Those three points a, b and c form a triangle with the tip being the L4 vertebra. The angle represented by this triangle is the C7 translation angle, C7TA (Fig. 7).
- Angle of femur obliquity (FOA) is measured as the inclination of the femoral axis to the vertical. Normally the femurs are vertical. If there is an angulation, this angle is the demonstration of certain amount of knee flexion. The knee flexion angle and the obliquity of the femur with a vertical line is the same. The knee flexion is a compensation phenomenon to allow the patient to stay balance but in a non-economic way. The femur obliquity, which is the complementary angle is easy to measure on regular full spine standing X-rays. This femur obliquity angle (FOA) should be added to the correction needed (Fig. 1b) to restore an appropriate balance.

- Angle of tilt compensation (PTCA): the pelvis tilt has a theoretical value, which is given by the Roussouly's classification [24] (Table 1). The pelvis tilt in accordance with pelvic incidence (PI) described by Legaye [18] is normally around 9–12° in type 1 and 2, approximately 13° in type 3 and can reach 20–25° or more in type 4. The average value for more than 80% of the population is around 15° [24]. If the pelvis tilt is higher than its theoretical value, then it is due to pelvis retroversion, which is a compensation phenomenon. Knowing the theoretical value of Pelvis Tilt (PT) provided it is easy to understand that a sensible difference between theoretical value and measured value is a compensation phenomenon. This abnormal pelvis retroversion angle should be added to the correction needed to restore a good balance. This is frequent in type 4 spine of the Roussouly's classification where the PT can be superior to 30° (Fig. 2). By experience it was decided that if the PT measured on standing X-rays was less than 25° or more than 25, 5 or 10° of tilt angle compensation should be added, respectively.

$$FBI \text{ angle of correction} = C7TA + FOA + PTCA$$

Types of correction techniques used to restore the balance should be adapted to the type of pathology and the amount of correction requested

*Interpedicular osteotomy (IPO) [5], often called Smith Petersen Osteotomy [2, 3]*

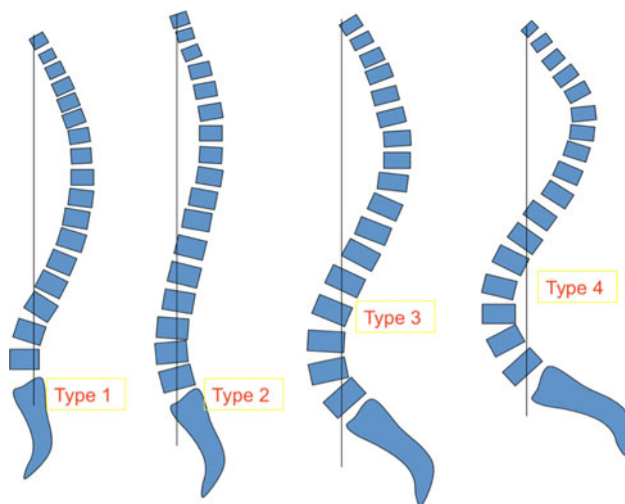
This technique involves resection of the laminae, facets and ligamentum flavum. This leaves a gap of about 1 cm, which is closed down by compression of the screws to shorten the posterior column. Approximately 8–10° of sagittal correction can be obtained if the anterior disc is still soft. An anterior support with an interbody cage located as far as possible in the front of the disc guarantees the best correction. Multiple levels can be operated to obtain a progressive and harmonious correction.

**Table 1** Pelvic parameters and sacral slope variation in asymptomatic volunteers Lumbar lordosis LL = SS (sacral slope) +15° (±1.2°)

	n	PI	PT	SS
A 28° < PI < 37.9°	12	35.4 ± 1.3 [33.7 to 37.9]	3.9 ± 4.5 [-1.5 to 13.3]	31.5 ± 5.2 [21.2 to 38.5]
B 38° < PI < 47.9°	44	42.7 ± 2.8 [37.9 to 47.6]	8.9 ± 4.8 [-5.1 to 18.2]	33.8 ± 4.8 [23.1 to 48.4]
C 48° < PI < 57.9°	59	52.6 ± 2.8 [48.2 to 57.4]	12.5 ± 5.6 [-1.2 to 23.2]	40.1 ± 5.5 [28.2 to 52.9]
D 58° < PI < 67.9°	26	62.6 ± 2.8 [58.2 to 67.6]	15.8 ± 4.3 [7.1 to 26.8]	46.8 ± 4.2 [37.9 to 58.5]
E 68° < PI < 77.9°	11	72.6 ± 2.8 [69.6 to 77.4]	19.7 ± 5.5 [12.6 to 27.9]	52.9 ± 5.2 [46.2 to 59.6]
F 78° < PI < 87.9°	2	81.4 ± 3.3 [79.1 to 81.4]	21.9 ± 12.3 [13.2 to 30.6]	59.5 ± 9 [53.1 to 65.9]

A, Type 1; B, type 2; C, type 3; DEF, type 4 according to Roussouly's classification





**Fig. 2** 4 types of spine according to Roussouly's classification

#### *Pedicle subtraction osteotomy (PSO) [4; Fig. 3]*

The PSO technique as described by Scudese [25] is performed when there is a rigid anterior and posterior column such as in ankylosing spondylitis. The apex of the wedge is centered on the vertebral body anteriorly and the base overlies the facet joints and laminae posteriorly. The area of the base runs from the foraminal space above to the foraminal space below in the sagittal plane and in the coronal plane runs from the inferior laminae of the adjacent superior vertebra to the inferior laminae below. The size of the wedge is determined by the angular correction needed. The lateral and posterior wall is then resected to avoid damage to the dura from retropulsion during reduction. Compression of the osteotomy gap continues until further movement is stopped by the margins of the previous laminotomies. The stability of the correction is supplemented with a rod-screw construct (Fig. 3). This is the most powerful correction technique using egg shell technique or osteome cutting according to the surgeon's preference.

*Other combinations are possible and should be adapted to the clinical situation to solve*

The solution is a mix of: asymmetrical pedicle subtraction osteotomy (in case of coronal plane deformities) or posterior vertebral column resection (PVCR) (in rigid deformities) allowing correction by angulation as well as translation [27].

#### Patient population

Two groups of patients underwent correction of imbalance spine using pedicle subtraction osteotomy  $\pm$  other techniques. The first group of 18 patients underwent pedicle subtraction osteotomy for fixed sagittal imbalance between

2001 and 2008 and was retrospectively analysed and the second group was prospectively operated between September 2008 and June 2010 using the FBI method to evaluate the correction needed.

#### *The first group (A)*

Twelve women and six men, with a mean age of 50.6 years (14–74 years), had an osteotomy by two surgeons at the same institution. Five patients had degenerative sagittal imbalance (DSI), eleven patients had iatrogenic sagittal imbalance (ISI) after a primary spine arthrodesis (failed back surgery syndrome with flat back) one patient had posttraumatic kyphosis (TK) and one patient had ankylosing spondylitis (AS) (Table 1).

No systemic co-morbidities contraindicated the surgical procedure. One patient had Parkinson disease and one patient had an undetermined genetic myopathy. Mean follow-up was 35.1 months (24 months–5 years).

Medical and surgical history was recorded. Diverse parameters such as walking distance, location and intensity of pain, physical activity and Oswestry disability index (ODI) were recorded during preoperative and every postoperative visit.

Surgical data included operating time, blood loss, blood transfusion and complications (infection, nerve root injury and dural tear).

The operative procedure always consisted of a posterior three-column wedge resection combined with a posterior arthrodesis and instrumentation.

Instrumentation was TSRH and Legacy (Medtronic<sup>®</sup>, Memphis USA). Peri-operative recuperation of the patient's blood loss limited the need for transfusion and these volumes were recorded. Somatosensitive and motor-evoked potentials were performed in all surgeries to limit neurological complications. Postoperative care included a thermoforming thoracolumbar orthotics for 2 months.

Radiological assessment consisted of standing (anteroposterior and profile) full spine imaging including the hips and femurs. Before 2007, long X-ray films were made; afterwards, the EOS system (Biospace, France) was used [9]. Pre- and postoperative imaging was done and an independent radiologist performed radiological analysis with a graduated and computerized goniometer. Patients who had their radiological assessment on the EOS systems were digitally analyzed.

Radiological follow-up was done at 2 weeks, 2, 6 months, 1 and 2 years after surgery until the last visit at 5 years.

Thoracic kyphosis and lumbar lordosis were determined as the Cobb angle between T5–T12 and T12–S1, respectively. Standard pelvic parameters such as pelvic incidence (PI), pelvic tilt (PT) and sacral slope (SS) were registered

[18]. For sagittal balance analysis we determined three reference points: midpoint of the endplate of S1 (S), the centre of the femoral heads (F) and the midpoint between F and S(M). If the femoral heads did not superpose, F was determined by the midpoint of a line drawn between the centers of both femoral heads. The relation between the C7 plumb line and these reference points allowed us to divide the patients into four postoperative groups: patients with the C7 plumb line in front of F (CF), between F and M (FCM), between M and S (MCS) and behind S (SC) (Fig. 2).

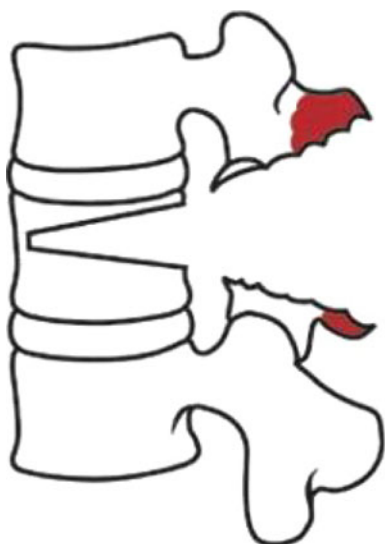The translation in centimetres (corrected for radiological magnification) of the C7 plumb line in relation to these three reference points indicated the importance of the osteotomy.

Hip flexion was measured as the inclination of the femoral axis to the plumb line.

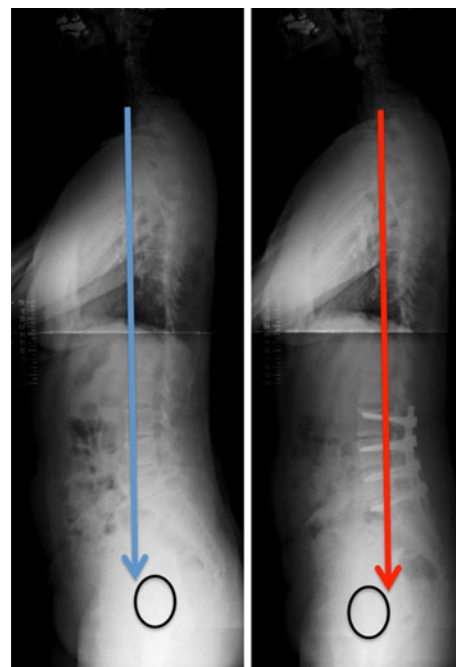
#### The second group (B)

Five women and three men, with a mean age of 48.6 years (39–77 years), underwent osteotomy performed by the same two surgeons at the same institution. Three patients had ankylosing spondylitis (AS) and five patients had iatrogenic sagittal imbalance (ISI) after a primary spine arthrodesis (failed back surgery syndrome with flat back). No systemic co-morbidities contraindicated the surgical procedure. Mean follow-up was 16.1 months (12 to 24 months). Exactly the same parameters as that for group A were recorded. In this group we used the FBI formula to calculate the theoretical correction needed (Fig. 4).

Clinical examination parameters and radiological measurements were performed the same way as in group A by the same radiologist.



**Fig. 3** Posterior transpedicular osteotomy: subtraction osteotomy



**Fig. 4** Symptomatic lumbar canal stenosis with back pain. Type 1 spine according to Roussouly's classification. Low pelvic incidence: 43°, preop: PT: 18°, C7 plumb line in front of S1 plateau and just in front of femoral head, it is compensated balance, femur are straight; Oswestry: 54%. FBI pre OP: C7TA (8°) + PTC (5°) + FOA (0°) = 13° Post op: one TLIF with Smith Petersen L5/S1, decompression 3 levels and fusion. PT: 11°, C7 plumb line through S1 plateau and just behind femoral head, it is a well balanced spine, femur are straight; Oswestry 18% at 1 year follow-up

## Results

### Surgical outcomes

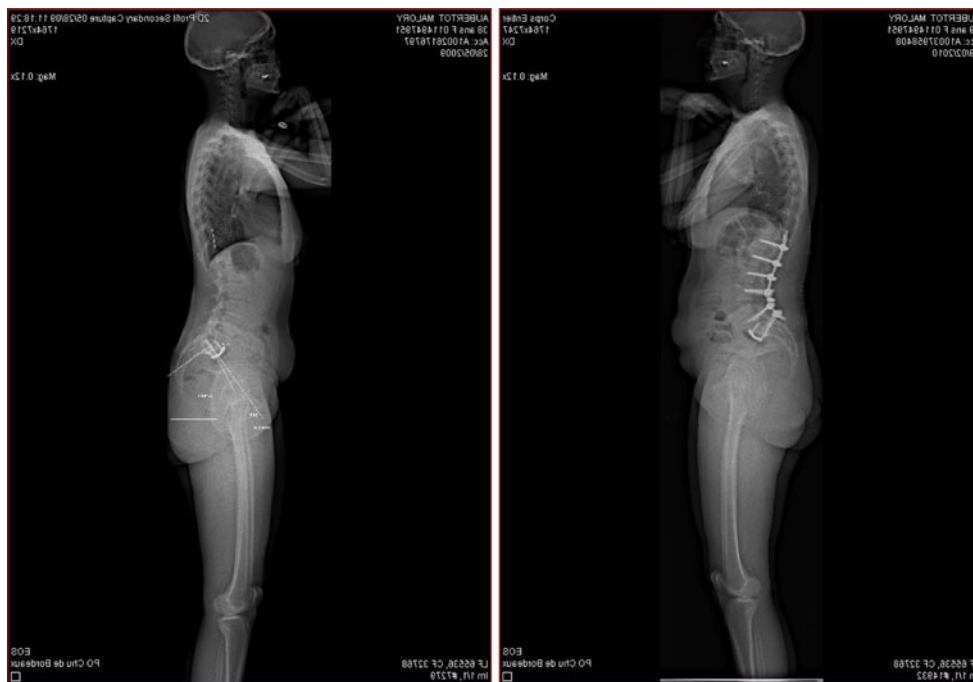- Group A: all patients had an osteotomy (PSO) located at levels: T12 (1), L2 (2), L3 (3), L4 (9), L5 (2) and one in the S1 plateau. 3 patients had an additional Smith Petersen osteotomy at the adjacent upper level of the PSO.

Mean calculated blood loss was 1,881 ml (660–3,900 ml). Mean operating time was 296 min (200–450 min). Arthrodesis was extended from S1 to upper thoracic spine (between T3 and T6) in ten cases.

No vascular injury was sustained and no perioperative deaths occurred. One patient had a dural tear that was repaired without complications. No neurological injuries or nerve root lesions are reported.

One patient had a superficial wound infection treated by surgery and antibiotic therapy. An osteoporotic impaction fracture due to corticotherapy provoked progressive kyphosis at the cephalic end of the arthrodesis in one patient. Arthrodesis in this patient was extended to the upper thoracic spine with excellent results at 4 years. According to the FBI technique calculated a posteriori the average amount of correction needed was 42.7°.

**Fig. 5** Patient type 4 spine because incidence is high: 78° Left: Preoperative (EOS) X-ray showing typical attitude with sagittal imbalance without femur obliquity, failed back surgery due to insufficient correction with the ALIF L5S1 and 3 previous posterior surgery performed without respect of balance Incidence: 78°, SS 46°. Oswestry: 62%. FBI pre OP: C7TA (20°) + PTC (10°) + FOA (0°) = 30° Right: Postoperative (EOS) X-ray after one level PSO of 30° at L4 showed corrected sagittal balance. C7 plumb line is through the S1 plateau, lumbar lordosis is 80°, OSW: 16% at 6 months' follow-up



- Group B: Five osteotomies (PSO) performed at level L4 and 3 at level L3. 3 add additional Smith Petersen). According to the FBI technique calculated pre-operatively the average amount of correction needed was 38.9° (Fig. 5).

Mean calculated blood loss was 1,825 ml (1,230–3,250 ml). Mean operating time was 256 min (180–350 min). No other complication occurred. Arthrodesis was extended from S1 to T4 in four cases and was located only in the lumbar spine for the remaining four cases. One patient had an early deep infection immediately debrided and treated with antibiotics and a complete recovery without implant removal.

#### Clinical outcomes

- Group A: Walking distance improved in all patients, and all but one patient walk without crutches. Mean pre- and postoperative ODI scores were 48.7 (18–84) and 26.66 (2–54), respectively; this is a 44.56% improvement.
- Group B: Walking distance improved in all patients. Mean pre- and postoperative ODI scores improved by 58.62%.

#### Radiological outcomes

##### Group A

Mean pre- and postoperative thoracic kyphosis was 31.2° (range 6–70°) and 35.8° (22–58°). Mean pre- and

postoperative lumbar lordosis was 20.7° (–22–49°) and 42.5° (16.5–66°), respectively. Mean correction through the osteotomy site was 26° (16–50°).

Mean pre- and postoperative PI was 57.8° (35 to 78°) and 53.88° (36 to 76°), respectively. Mean pre- and postoperative PT was 31.35° (15 to 50°) and 23.9° (11 to 42°), respectively. Mean SS was 26.41° (6 to 45°) preoperative and 35.3° (14 to 51°) postoperatively. Femur obliquity measurements improved from 11.8° (–3 to 23°) preoperative to 4.6° (–5 to 18°) postoperative.

Mean sagittal balance improved from 5.75 cm in front of the femoral heads (15 cm in front to 5.4 cm behind the femoral heads) to 0.1 cm in front of the femoral heads (6.6 cm in front to 5 cm behind the femoral heads). The mean C7 plumb line translation was 6.21 cm (–4.8 to 13.7 cm).

Using retrospectively the FBI technique, the amount of correction requested should have been 42.7° but the correction obtained with the osteotomy was not sufficient in eight cases (sub group CF) on the post-operative X-rays as the C7 plumb line position was still positive. It was decided to better analyse the results according to the theoretical value of FBI requested and the C7 plumb line correction obtained postoperatively. In group FCM the C7 plumb line was better and located just behind the femoral head and finally in group MSC and SC the C7 plumb line was located close to the S1 plateau and behind the femoral head. The osteotomy correction (PSO) was associated with additional osteotomies (Smith Petersen) in eight cases so that the angle of correction requested calculated using the FBI method was obtained or nearly obtained. For those two groups the Oswestry improvement was significantly better.



### Subgroups in group A

The CF group (8 patients) had a mean preoperative ODI of 61.4 improving to 35.4 postoperative (39.5%). Mean C7 posterior translation was 1.8 cm (5.3 to  $-4.8$  cm). Femur obliquity improved from  $14.14^\circ$  (4 to  $23^\circ$ ) to  $5.4^\circ$  (18 to  $-5^\circ$ ). Mean improvement was  $8.7^\circ$ . Theoretical FBI value was  $45.3^\circ$ , and correction obtained was not sufficient as all patients had a C7 plumb line located in front of femoral head.

The FCM group (4 patients) had a mean preoperative ODI of 46.5 improving to 23.3 postoperative (50.13%). Mean C7 posterior translation was 9.8 cm (1.9 to 13.7 cm). Femur obliquity improved from  $12.75^\circ$  (5 to  $20^\circ$ ) to  $6.25^\circ$  (5 to  $10^\circ$ ) with a mean of  $6.5^\circ$ . Theoretical FBI value was  $39.5^\circ$  and the correction obtained by the PSO was insufficient because C7 plumb line was at the level of the femoral head postoperatively.

The MCS group (5 patients) presented a mean improvement of the ODI from 35.5 to 15 pre- and postoperative, respectively (33.87%). Mean C7 posterior translation was 6.25 cm ( $-0.5$  to 10.3 cm). Mean Femur obliquity improvement was from  $11.7^\circ$  ( $-3$  to  $18^\circ$ ) to  $2.58^\circ$  (range 0 to  $12^\circ$ ). Two patients in this group needed repeated surgery. Theoretical FBI value was  $42.7^\circ$ , and correction was obtained with 1 or 2 additional Smith Petersen (SP) in all cases except one. Only one patient was in the SC group; she had an excellent balance restoration and femur vertical. This patient underwent his sixth revision surgery for a crankshaft phenomenon on an infantile scoliosis. To outline the results we can say that patients improved by a mean 63% on the ODI and that all the C7 plumb lines were translated posteriorly in an economical balance behind the femoral head.

### Group B

The mean preoperative ODI improved postoperatively by 58.62%. Mean C7 posterior translation was 7.2 cm (2.8 cm in front of femoral head to  $-4.4$  cm behind femoral head). Postoperatively, five patients were in the position MCS and three in the position SC. Femur obliquity improved from  $10.3^\circ$  (0 to  $21^\circ$ ) to  $1.8^\circ$  (5 to  $0^\circ$ ). Mean improvement was  $8.5^\circ$ . Theoretical FBI value was  $38.9^\circ$ , and correction was obtained by PSO in all cases and additional Smith Petersen (SP) in five cases. Knowing the amount of correction needed it was easy to determine if the PSO must be completed with an other technique of correction to reach the appropriate angle. One possible technique is the SP (Smith Petersen) to obtain additional lordosis correction as requested by the FBI calculation method.

Radiological outcomes: all results are presented in Tables 2, 3, 4, 5, 6, 7)

**Table 2** Group A patient, diagnosis, osteotomy level and correction performed at the osteotomy level

Patient	Diagnostic	Osteotomy level	Correction in the osteotomy site
1	DSI	L3	$23^\circ$
2	ISI	L3	$26^\circ$
3	TK	L2	$16^\circ$
4	ISI	L4	$16^\circ$
5	AS	L4	$34^\circ$
6	ISI	L3	$37^\circ$
7	ISI	D12	$50^\circ$
8	ISI	L5	$26^\circ$
9	ISI	S1	$26^\circ$
10	DSI	L4	$21^\circ$
11	ISI	L2	$22^\circ$
12	ISI	L4	$18^\circ$
13	ISI	L4	$21^\circ$
14	DSI	L4	$40^\circ$
15	DSI	L4	$28^\circ$
16	ISI	L5	$20^\circ$
17	DSI	L4	$24^\circ$
18	ISI	L4	$20^\circ$
Average			$26^\circ$

DSI Degenerative sagittal imbalance, ISI iatrogenic sagittal imbalance, TK posttraumatic kyphosis, AS ankylosing spondylitis

**Table 3** Group B patient, diagnosis, osteotomy level and correction performed at the osteotomy level

Patient	Diagnostic	PS osteotomy level	Correction in the osteotomy site
1	AS	L4	$28^\circ$
2	ISI	L4	$26^\circ$
3	AS	L3	$22^\circ$
4	ISI	L4	$31^\circ$
5	AS	L4	$34^\circ$
6	ISI	L3	$29^\circ$
7	ISI	L4	$29^\circ$
8	ISI	L3	$30^\circ$
Average			$28^\circ$

ISI Iatrogenic sagittal imbalance, AS ankylosing spondylitis

### Discussion

Vertebral osteotomy (OST) is a well-known technique for sagittal correction of the spine. Various authors have presented different techniques and results. Smith-Petersen OST achieves an average correction of  $10^\circ$  [5]. Posterior wedge OST results in corrections from 24 to  $35^\circ$  depending on if they are done using a chisel or as an eggshell procedure [15–17, 21, 23, 27, 30]. Blood loss and corrections obtained in our study are comparable to other eggshell OST [2, 15].

**Table 4** Postoperative groups

Groups	Patient	Femur obliquity pre-op	Femur obliquity post-op	Pelvic incidence	Pre op PT	PT compensation	C7 translation angle	PSO correction	Additional	Retrospective FBI pre op calculation C7TA + FOA + PTC	C7 Pb line pre-op (cm)	C7 Pb line post-op (cm)	ODI improvement (%)
CF	2	20°	5.5°	55°	15°	5°	15°	26°		15° + 20° + 5° = 40°	+9.1	+3.8	48.38
	4	23°	5°	67°	47°	10°	22°	18°		22° + 23° + 10° = 55°	+1	+5.3	53.50
	8	15°	5°	50°	28°	10°	25°	26°		25° + 15° + 10° = 50°	+15	+2	48
	10	18°	18°	62°	56°	10°	20°	21°		20° + 18° + 10° = 48°	+0.7	+5.5	57.8
	11	18°	5°	59°	39°	10°	20°	22°		20° + 18° + 10° = 48°	+4.2	+4	33.33
	12	4°	-5°	63°	18°	5°	20°	18°		20° + 4° + 5° = 29°	+1.6	+0.77	20.58
	14	15°	10°	43°	22°	5°	34°	40°		34° + 15° + 5° = 54°	+6.2	+6.6	23.52
	18	6°	0°	55°	30°	10°	23°	20°		23° + 6° + 10° = 39°	-0.4	+1.5	
FCM	3	11°	5°	43°	21°	5°	15°	16°	1 SP	15° + 11° + 5° = 31°	+1.2	-0.7	48
	5	15°	5°	35°	29°	10°	20°	34°	1 SP	20° + 15° + 10° = 45°	+15	-1.3	52
	15	20°	10°	76°	50°	10°	22°	28°		22° + 20° + 10° = 52°	+12.7	0	43.75
	17	5°	5°	54°	19°	5°	20°	24°	1 SP	20° + 5° + 5° = 30°	+11	-2	66.66
	1	15°	12°	63°	44°	10°	23°	23°	2 SP	23° + 15° + 10° = 48°	+2	-3.4	88.88
MCS SC	7	0°	0°	67°	22°	5°	40°	50°	1 SP	40° + 0° + 5° = 45°	-5.4	-3.3	72
	9	17°	3.5°	63°	32°	10°	18°	26°	2 SP	18° + 17° + 10° = 45°	+8	-2.3	60
	13	18°	0°	63°	38°	10°	22°	21°	2 SP	22° + 18° + 10° = 50°	+6	-3.8	42.85
	16	0°	0°	51°	15°	5°	20°	20°	-	20° + 0° + 5° = 25°	-2.2	-1.7	56.25
	6	5°	0°		27°	10°	37°	25°	1 SP	25° + 0° + 10° = 35°	+1.5	-5	60
	Average		11.8°	4.6°							41.3°		
										42.7°		+5.75	

CF, FCM, MCS and SC according to the position of C7 plumb line

+ means in front of centre of femoral heads, - means behind centre of femoral heads

C7 plumb line is always behind the femoral head and through the S1 plateau in sub group MSC and SC

C7 plumb line is always in front of the femoral head in sub group: CF and just behind femoral head in group FCM

FBI pre-op calculation: C7TA + FOA + PTC showed a good correction with C7 plumb line behind femoral head in subgroup MSC and SC

**Table 5** Postoperative groups. CF, FCM, MCS and SC see text

Patient	Femur obliquity pre-op	Femur obliquity post-op	Pelvic incidence	Pre op PT	PT	C7 translation angle	PSO correction	Additional Correction chevron	FBI pre op calculation C7TA + FOA + PTC	C7 Pb line pre-op—FH (cm)	C7 Pb line post-op—FH	ODI improvement (%)
1	15°	2°	53°	26°	10°	19°	28°	2	19° + 15° + 10° = 44°	+2	-3	82
3	0°	0°	39°	19°	5°	20°	26°	-	20° + 0° + 5° = 25°	+5	-4	57
5	17°	3.5°	37°	20°	5°	15°	22°	1	15° + 17° + 5° = 37°	+7	-3	64
7	18°	0°	53°	15°	10°	22°	31°	1	22° + 18° + 0° = 40°	+4	-4.8	55
8	0°	0°	68°	27°	10°	30°	34°	-	30° + 0° + 10° = 40°	-1.2	-4.7	56
2	10°	5°	60°	30°	10°	21°	29°	1	21° + 10° + 10° = 41°	+0.5	-7	63
4	5°	0°	50°	26°	5°	20°	29°	-	20° + 5° + 10° = 35°	+1.5	-5	40
6	15°	4°	47°	17°	5°	29°	30°	2	29° + 15° + 5° = 49°	+4	-3.8	52
Average	10.3°	1.8°							38.87°	+2.8	-4.4	58.62

+ means in front of centre of femoral heads, - means behind centre of femoral heads

C7 plumb line is always behind the femoral head and through the S1 plateau

FBI pre-op calculation: C7TA + FOA + PTC showed a good correction with C7 plumb line behind femoral head and in group MSC and SC

**Table 6** Pelvic parameters pre- and postoperative: some post PT are equivalent to pre-op and higher than expected according to Table 1, probably because of insufficient correction. So there is always a compensation

Patient	Pelvic incidence pre-op	Pelvic incidence post-op	Sacral slope pre-op	Sacral slope post-op	Pelvic tilt pre-op	Pelvic tilt post-op
1	63°	62°	19°	39°	44°	23°
2	54°	55°	39°	39°	15°	16°
3	43°	43°	22°	25°	21°	18°
4	66°	67°	19°	30°	47°	37°
5	35°	36°	6°	14°	29°	22°
6	57°	54°	30°	42°	27°	14°
7	67°	68°	45°	51°	22°	17°
8	50°	50°	22°	26°	28°	24°
9	78°	76°	46°	53°	32°	23°
10	63°	62°	7°	20°	56°	42°
11	59°	59°	20°	26°	39°	33°
12	63°	63°	43°	36°	18°	27°
13	63°	63°	25°	32°	38°	23°
14	46°	43°	24°	32°	22°	11°
15	76°	76°	26°	38°	50°	38°
16	51°	55°	36°	32°	15°	24°
17	54°	54°	35°	42°	19°	12°
18	55°	55°	25°	28°	30°	27°

The typical position with flexed femur and knees helps the patients to cope with their sagittal imbalance. Patients adjust their coping mechanism by straightening their legs after OST surgery (Fig. 6). The increasing hip extension leads to disappointing sagittal correction, although the patient has a better posture of his lower limbs and simultaneously restores a more appropriate pelvis tilt. (Fig. 1b, c).

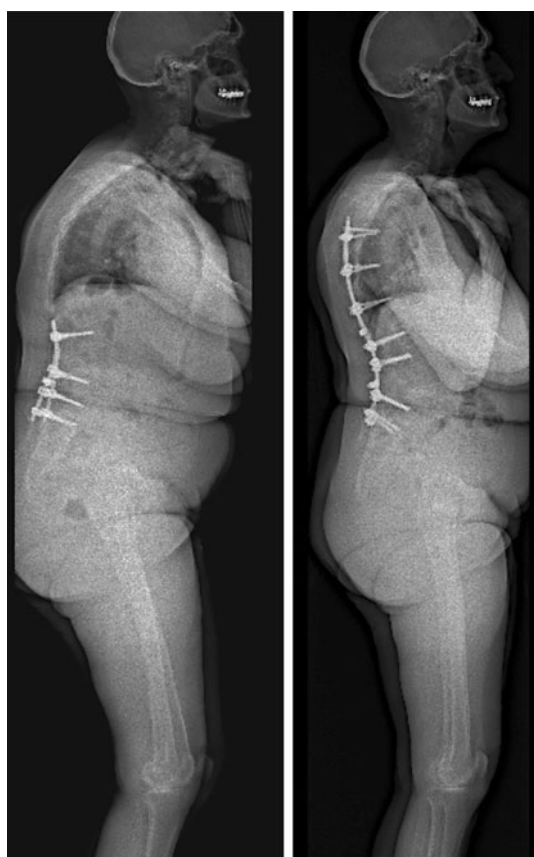In our group A, the mean correction was 28.6° and corresponded to a triangle with the pedicle height as base (Fig. 7).

Historically, most osteotomies to correct kyphosis were done in the lumbar spine because of the proximity of the spinal cord with higher osteotomies (Fig. 8). The biomechanical advantage of performing the osteotomy in the lumbar spine is that with a longer lever arm the angle of correction required is less [27]. According to Roussouly's classification L4 vertebra is the most common place for the lumbar apex curve. This places less stresses on the implants and minimises the risk of fatigue failure. The disadvantage is that it does not directly address the main deformity. With an osteotomy closer to the apex of the deformity a greater angle of correction is required. This places larger stresses on the implants.

A corrective osteotomy in the lumbar can change the harmonious relationship described by Roussouly [24] in such a way as to alter the surface topography of the lumbar

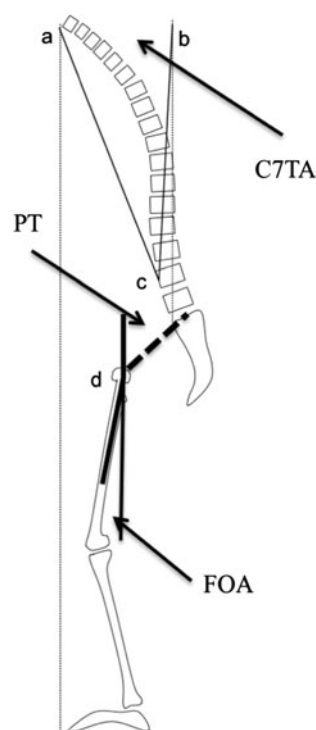
**Table 7** Pelvic parameters pre- and postoperative

Patient	Pelvic incidence pre-op	Pelvic incidence post-op	Sacral slope pre-op	Sacral slope post-op	Pelvic tilt pre-op	Pelvic tilt post-op
1	53°	53°	29°	35°	24°	18°
2	60°	61°	30°	41°	30°	20°
3	39°	41°	20°	23°	19°	18°
4	50°	51°	24°	29°	26°	22°
5	37°	37°	17°	20°	20°	17°
6	47°	45°	30°	40°	17°	15°
7	53°	55°	38°	39°	15°	16°
8	68°	67°	41°	44°	27°	23°



**Fig. 6** Patient no. 13. Left: Preoperative (EOS) X-ray showing typical attitude with sagittal imbalance and femur obliquity: PRE OP FBI calculation: C7TA (20°) + PT C (10°) + FOA (18°) = 48°. Right: Postoperative (EOS) X-ray after one PSO at L4 with corrected sagittal balance, C7 plumb line at the level of S1 plateau and but femur still have some degrees of remaining obliquity and PT still high at 30°: conclusion the balance is restored but not perfect. Applying the FBI technique post op shows that correction obtained is 36° so ideally 12° more correction would be better

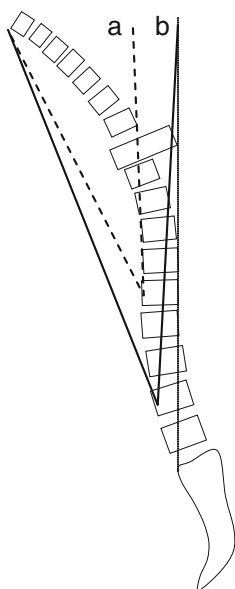
region. This may lead to an over or under corrective compensatory response from the pelvis. The implications are that a mismatch of the lumbo-pelvic profile may occur. For example, where the pelvic incidence of an individual is



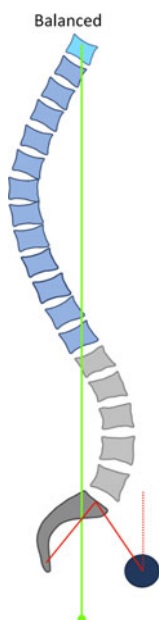
**Fig. 7** Preoperative planning. C7 translation angle: C7TA. Midpoint of C7 inferior plateau (a) is translated on the plumb line ascending from the mid part of the S1 plateau (b). Point c is on the anterior cortex of the selected vertebra for osteotomy, which is mainly L4 vertebra. Femur obliquity angle: FOA. Femur flexion is measured as the angle between the femoral axis and the plumb line (d). Pelvic compensation angle: PTA. Pelvic tilt is measured as usual: line between center femoral head to mid part of S1 plateau and vertical line. If PT between 15 and 25: add 5°. If PT superior 25° add 10°

greater than 70° the lumbar lordosis would be expected to be proportional. This would indicate a large lordotic curve between L1 and S1. The apex of this type of curve is usually at L2 or L3. An osteotomy at L4 would move the apex distally and create a short lordotic curve, which extends into the proximal lumbar segments in a linear fashion. A compensatory pelvic response is needed to accommodate this change in shape. Problems arise when

**Fig. 8** **a** and **b** are triangles with the same angle and thus the same quantity of OSTEOTOMY as explained in Fig. 6, it is clear that the translation with the Osteotomy is less important when performed at a higher level because for the same angle the C7 plumb line translation stays more anterior



**Fig. 9** Ideal balance with C7 plumb line at the posterior part of S1 plateau



this response is insufficient. This is the reason why the knowledge of the spine and pelvis shape is so important to find the best compromise and sometimes the theoretical correction cannot be obtain but at least the C7 plumb line should be behind the femoral heads with the femur in vertical position (Fig. 9).

The analysis of the results in both groups showed that the FBI technique was a correct approximation of the amount of correction needed in order to obtain a C7 plumb line passing through S1 plateau. The retrospective group A study showed insufficient correction as the calculation did not include the femur obliquity and the Tilt compensation for patients with high incidence angle. In group A when the theoretical value of correction requested retrospectively

was obtained in accordance with the FBI, C7 plumb line was good and the clinical outcomes better. This validated the FBI technique even if a greater number of cases are mandatory.

In all cases there was a need to evaluate the amount of correction requested. In flexible spine there was always adaptation capacity of the non-instrumented level and for this reason flexion/extension X-rays were important to perform to evaluate this parameter which was not very important because we had an old population. For angular kyphosis, the deformity would be localized and the imbalance mechanism easy to understand with a correction focusing at the level of the angular kyphosis with restoration of the normal sagittal shape using a short construct.

## Conclusion

Sagittal balance is a key point to have a better understanding of low back pain and failed back surgery. PSO combined with IPO or Smith Petersen was the most common technique for segmental deformity in kyphosis. The position of the femur shaft representing the knee flexion was an important parameter to analyse in standing position to avoid undercorrection leading to insufficient correction and remaining spine imbalance. Pelvis tilt angle restoration confirms the efficiency of the calculation method and should be measured adequately particularly for patients with high pelvic incidence who have a bigger possibility of pelvic retroversion. Patients with high pelvic incidence and kyphotic imbalance are much more demanding for correction compared with patients with small pelvic incidence.

Our experience confirms the value of our formula as all patients had a C7 plumb line close to the sacral plateau, which was considered as the best equilibrium. This FBI technique can be used even for limited lordosis restoration in case of short fusion. The FBI calculation allows a good evaluation of the amount of correction needed and provides the surgeon the appropriate information for the adequate technique to use in order to obtain a good balance.

**Conflict of interest** None.

## References

1. Aurouer N, Obeid I, Gille O, Pointillart V, Vital JM (2009) Computerized preoperative planning for correction of sagittal deformity of the spine. *Surg Radiol Anat*, Jul 14. [Epub ahead of print]
2. Bridwell KH, Lewis SJ, Edwards C, Lenke LG, Iffrig TM, Berra A, Baldus C, Blanke K (2003) Complications and outcomes of pedicle subtraction osteotomies for fixed sagittal imbalance. *Spine (Phila Pa 1976)* 28(18):2093–2101



3. Bridwell KH, Lewis SJ, Lenke LG, Baldus C, Blanke K (2003) Pedicle subtraction osteotomy for the treatment of fixed sagittal imbalance. *J Bone Joint Surg Am* 85-A(3):454–463
4. Bridwell KH, Lewis SJ, Rinella A, Lenke LG, Baldus C, Blanke K (2004) Pedicle subtraction osteotomy for the treatment of fixed sagittal imbalance. Surgical technique. *J Bone Joint Surg Am* 86-A(Suppl 1):44–50
5. Burton DC (2006) Smith-Petersen osteotomy of the spine. *Instr Course Lect* 55:577–582
6. Caputy AJ, Spence CA, Bejjani GK, Luessenhop AJ (1997) The role of spinal fusion in surgery for lumbar spinal stenosis: a review. *Neurosurg Focus* 3(2):e3 discussion 1 p following e4
7. Chiffolot X, Lemaire JP, Bogorin I, Steib JP (2006) Pedicle closing-wedge osteotomy for the treatment of fixed sagittal imbalance. *Rev Chir Orthop Reparatrice Appar Mot* 92(3):257–265
8. Debarge R, Demey G, Roussouly P (2010) Radiological analysis of ankylosing spondylitis patients with severe kyphosis before and after pedicle subtraction osteotomy. *Eur Spine J* 19:65–70
9. Dubouset J, Charpak G, Skalli W, Kalifa G, Lazennec JY (2007) EOS stereo-radiography system: whole-body simultaneous anteroposterior and lateral radiographs with very low radiation dose. *Rev Chir Orthop Reparatrice Appar Mot* 93(6 Suppl):141–143
10. Gill JB, Levin A, Burd T, Longley M (2008) Corrective osteotomies in spine surgery. *J Bone Joint Surg Am* 90(11):2509–2520
11. Glassman SD, Bridwell K, Dimar JR, Horton W, Berven S, Schwab F (2005) The impact of positive sagittal balance in adult spinal deformity. *Spine (Phila Pa 1976)* 30(18):2024–2029
12. Ikenaga M, Shikata J, Takemoto M, Tanaka C (2005) Clinical outcomes and complications after pedicle subtraction osteotomy for correction of thoracolumbar kyphosis. *J Neurosurg Spine* 6(4):330–336
13. Jang JS, Lee SH, Min JH, Kim SK, Han KM, Maeng DH (2007) Surgical treatment of failed back surgery syndrome due to sagittal imbalance. *Spine (Phila Pa 1976)* 32(26):3081–3087
14. Joseph SA Jr, Moreno AP, Brandoff J, Casden AC, Kuflik P, Neuwirth MG (2009) Sagittal plane deformity in the adult patient. *J Am Acad Orthop Surg* 17(6):378–388
15. Kiaer T, Gehrchen M (2010) Transpedicular closed wedge osteotomy in ankylosing spondylitis: results of surgical treatment and prospective outcome analysis. *Eur Spine J* 19:57–64
16. Kim YJ, Bridwell KH, Lenke LG, Cheh G, Baldus C (2007) Results of lumbar pedicle subtraction osteotomies for fixed sagittal imbalance: a minimum 5 year follow-up study. *Spine (Phila Pa 1976)* 32(20):2189–2197
17. Kim YJ, Bridwell KH, Lenke LG, Rhim S, Cheh G (2006) Sagittal thoracic decompensation following long adult lumbar spinal instrumentation and fusion to L5 or S1: causes, prevalence, and risk factor analysis. *Spine (Phila Pa 1976)* 31(20):2359–2366
18. Legaye J, Duval-Beaupère G, Hecquet J et al (1998) Pelvic incidence: a fundamental pelvic parameter for three-dimensional regulation of spinal sagittal curves. *Eur Spine J* 7:99–103
19. Leijssen P, Duarte M, Aunoble S, Fisher E, Le Huec JC (2010) Posterior wedge osteotomy for imbalance spine new method of evaluation: FBI technique. *Eur Spine J* 19(Suppl 3):S233–S364
20. Lovejoy CO (2005) The natural history of human gait and posture. Part 2. Hip and thigh. *Gait Posture* 21(1):113–124
21. Murrey DB, Brigham CD, Kiebzak GM, Finger F, Chewning SJ (2002) Transpedicular decompression and pedicle subtraction osteotomy (eggshell procedure): a retrospective review of 59 patients. *Spine (Phila Pa 1976)* 27(21):2338–2345
22. Ondra SL, Marzouk S, Koski T, Silva F, Salehi S (2006) Mathematical calculation of pedicle subtraction osteotomy size to allow precision correction of fixed sagittal deformity. *Spine (Phila Pa 1976)* 31(25):E973–E979
23. Rose PS, Bridwell KH, Lenke LG, Cronen GA, Mulconrey DS, Buchowski JM, Kim YJ (2009) Role of pelvic incidence, thoracic kyphosis, and patient factors on sagittal plane correction following pedicle subtraction osteotomy. *Spine (Phila Pa 1976)* 34(8):785–791
24. Roussouly P, Gollogly S, Berthonnaud E, Dimnet J (2005) Classification of the normal variation in the sagittal alignment of the human lumbar spine and pelvis in the standing position. *Spine (Phila Pa 1976)* 30(3):346–353
25. Scudese VA, Calabro JJ (1963) Vertebral Wedge Osteotomy. Correction of Rheumatoid (Ankylosing) Spondylitis. *Jama* 186:627–631
26. Tai CL, Hsieh PH, Chen WP, Chen LH, Chen WJ, Lai PL (2008) Biomechanical comparison of lumbar spine instability between laminectomy and bilateral laminotomy for spinal stenosis syndrome—an experimental study in porcine model. *BMC Musculoskelet Disord* 9:84
27. van Royen BJ, Scheerder FJ, Jansen E, Smit TH (2007) ASKyphoplan: a program for deformity planning in ankylosing spondylitis. *Eur Spine J* 16(9):1445–1449
28. Vosse D, van der Heijde D, Landewe R, Geusens P, Mielants H, Dougados M, van der Linden S (2006) Determinants of hyperkyphosis in patients with ankylosing spondylitis. *Ann Rheum Dis* 65(6):770–774
29. Yang BP, Chen LA, Ondra SL (2008) A novel mathematical model of the sagittal spine: application to pedicle subtraction osteotomy for correction of fixed sagittal deformity. *Spine J* 8(2):359–366
30. Yang BP, Ondra SL, Chen LA, Jung HS, Koski TR, Salehi SA (2006) Clinical and radiographic outcomes of thoracic and lumbar pedicle subtraction osteotomy for fixed sagittal imbalance. *J Neurosurg Spine* 5(1):9–17