

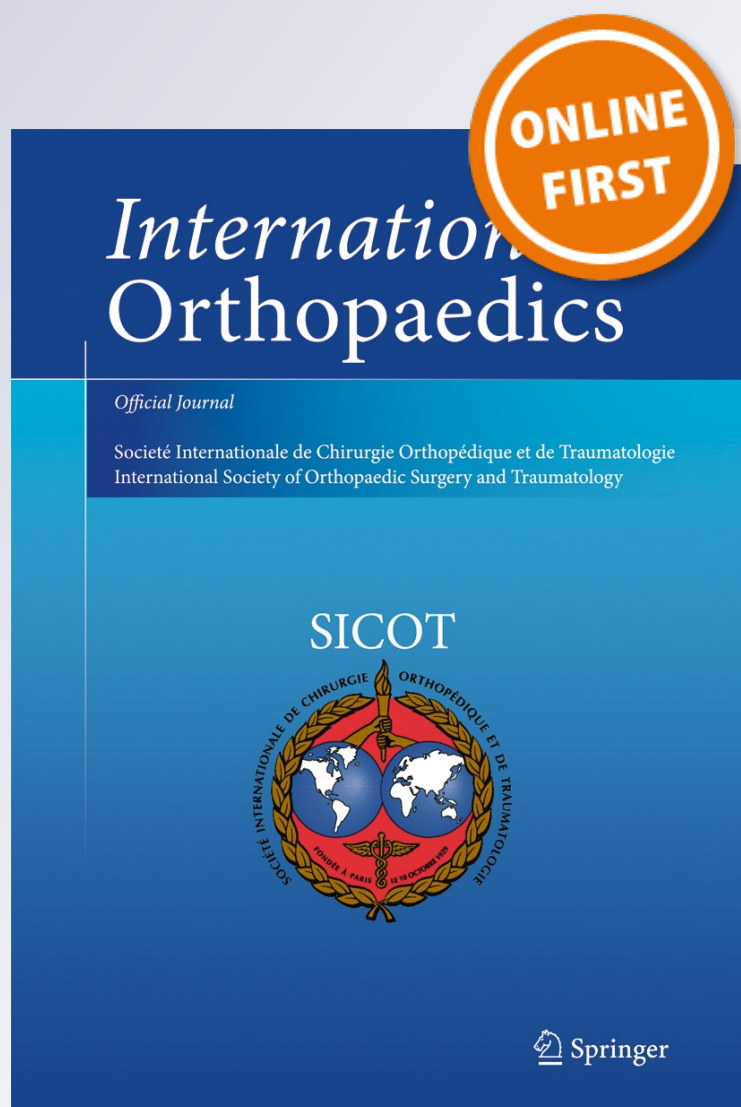
Role of a collagen membrane in adhesion prevention strategy for complex spinal surgeries

Jean-Charles LeHuec, Rachid Sadikki, Arnaud Cogniet, Julien Rigal, Hugues Demezou & Stéphane Aunoble

International Orthopaedics

ISSN 0341-2695

International Orthopaedics (SICOT)
DOI 10.1007/s00264-015-2767-x



Your article is protected by copyright and all rights are held exclusively by SICOT aisbl. This e-offprint is for personal use only and shall not be self-archived in electronic repositories. If you wish to self-archive your article, please use the accepted manuscript version for posting on your own website. You may further deposit the accepted manuscript version in any repository, provided it is only made publicly available 12 months after official publication or later and provided acknowledgement is given to the original source of publication and a link is inserted to the published article on Springer's website. The link must be accompanied by the following text: "The final publication is available at link.springer.com".

Role of a collagen membrane in adhesion prevention strategy for complex spinal surgeries

Jean-Charles LeHuec¹ · Rachid Sadikki¹ · Arnaud Cogniet¹ · Julien Rigal¹ · Hugues Demezou¹ · Stéphane Aunoble¹

Received: 18 February 2015 / Accepted: 18 March 2015
© SICOT aisbl 2015

Abstract

Purpose Following lumbar spine surgery, postoperative complications can appear, including epidural adhesions. The formation of fibrosis around the dura mater can, on the one hand, lead to compression of the nerve roots with recurrent radicular pain and, on the other hand, can increase the risks of specific complications at spinal re-intervention (haematomas and dural breaches). The aim of this prospective monocentric study was to assess the safety of a new collagen antiadhesion membrane in vertebral osteotomy surgery where scar tissue and adhesions are important.

Methods Twenty-six patients consecutively operated for lumbar posterior subtraction osteotomy with implantation of a collagen-based anti-adhesion membrane were evaluated. Membrane tolerance was evaluated at the short and midterm during the regular follow-up.

Results At six months' follow-up, postoperative pain [visual analogue scale (VAS)] and disability (Oswestry Disability Index score) were significantly reduced 33.1 and 43.1 %, respectively. These results were confirmed at 12-months' follow-up, with a decrease in pain of 39.9 % and in disability of 49.3 %. Amongst the observed postoperative complications was neither spinal fluid leak nor durotomy. Presence of the membrane was not related to complications. Two patients required further surgery for infection and nonunion at the osteotomised level. Adhesions to the dura mater were limited and thin, facilitating exposure.

Conclusions This study shows good tolerance of the collagen based membrane for spinal osteotomy and its

satisfactory use for preventing postoperative epidural adhesions. Good surgical practice associated with an anti-adhesion barrier may decrease fibrosis formation and improve postoperative functional results.

Keywords Pedicle subtraction osteotomy · Adhesion · Complications

Introduction

Spinal deformities of degenerative or iatrogenic origin are very disabling and have major physical, psychological and social impacts. Due to inevitable disc degeneration, the loss of mechanical properties of the discs leads to loss of physiological lumbar lordosis. When serious, this can cause sagittal imbalance, for which the patient tries to compensate using the back muscles and pelvic retroversion [1]. Beyond a certain limit, surgery becomes the only possible treatment by which to restore sagittal balance. Vertebral osteotomies are indicated when the deformity is too rigid to be corrected either with instrumentation alone or with simple facet-joint release or Smith-Petersen osteotomy [2].

Pedicular subtraction osteotomy (PSO) allows deformation correction but comes with well-known postoperative complications: haematomas, pseudoarthrosis, infections, fibrous epidural adhesions and potential radicular neurological deficit. The formation of postoperative adhesions is an uncontrollable healing phenomenon of injured tissues that occurs in the days following surgery. Tissues or organs that normally do not connect may be linked due to these adhesions, which can cause major clinical after effects. In lumbar spine surgery, Ross et al. [3] demonstrated that adhesions around the dura mater can cause compression of

✉ Jean-Charles LeHuec
j-c.lehuec@u-bordeaux2.fr

¹ Bordeaux University Hospital, Orthospine Unit 2, Bordeaux, France

nerve roots, which may cause recurrent radicular pain. The presence of postoperative fibrosis is a consequence of fibrin formation in the epidural space surrounding the nerve root. This process is initialised by violation of epidural tissues, consecutive to the intracanal surgical procedure [4, 5]. Tissue adhesion is a problem in revision surgery for anterior approaches due to the vicinity of fragile structures such as veins [6]. When performing a posterior revision procedure, adhesion to the dura is the most important challenge. Epidural fibrosis affects the normal dynamics of exiting nerve roots and ganglions by tethering them at the operative site. Nerve root ischemia caused by tethering may be an important contributing cause for the generation of radicular pain [5, 7–9]. Re-operation is always complex and dangerous after extensile dura mater and nerve root exposure. During re-operations, which appear in 15–18 % of lumbar surgeries in the five years following [10], the presence of adhesions increases the risks of operative complications such as haemorrhages and dural breaches. Preventing postoperative adhesions is essential in order to decrease neuro-pathic pain.

In addition to good surgical technique associated with good haemostasis, numerous materials have been applied to the spinal dura mater to reduce the formation of postsurgical epidural adhesions [11–13]—haemostatic sponges [14], hyaluronic acid [15], carboxymethylcellulose gels [16], fat-tissue flaps [17–19]—but the rare randomised studies did not report on improvement in postoperative pain and outcomes [20–22].

The objective of this prospective clinical study was to evaluate the safety of a resorbable collagen membrane (RCM) indicated in preventing adhesions, COVA™, which is placed on the dura mater at the end of the PSO in order to create a physical barrier from the surrounding haematoma and bone-graft material (Fig. 1).

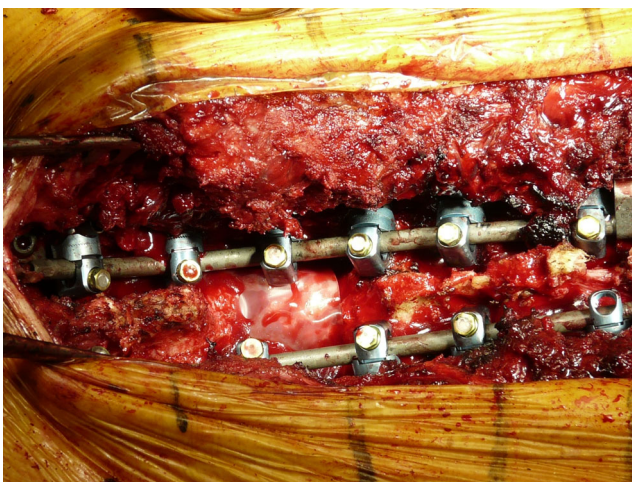


Fig. 1 Peroperative view of osteomized level, with dura mater covered by COVA collagen membrane

Material and methods

Between April 2010 and December 2012, a prospective observational study was conducted on 26 patients in our clinic. All patients had prior sagittal imbalance associated with chronic low back pain, which could not be improved by conservative methods performed over at least a one year period. All patients undergoing vertebral osteotomy were consecutively included in the study, and an RCM was placed on the dural sac without suture before closure of the muscle layers at the end of the procedure. Patients were followed for at least 12 months, and functional data were collected at six and 12 months postoperatively. Exclusion criteria were any contraindications to surgery. The main study objective was to analyse postoperative complications related to the antiadhesion medical device. Secondary objectives were to study the evolution of the Oswestry Disability Index (ODI), the most commonly recommended condition-specific outcome measure for spinal disorders; evolution of pain measured using the visual analogue scale (VAS); and RCM efficacy in the event of re-operation, evaluated according to the presence or absence of adhesions and ease of dissection, particularly at the level where the dura was exposed.

Diagnosis

Pre-operative clinical evaluation included a complete neurological examination and analysis of the overall posture according to the criteria of lumbar kyphosis and bending of the knees. Sagittal imbalance was confirmed using the EOS low-dose X-ray system (EOS Imaging, Paris, France), which provided 2D and 3D imaging of the full body in a standing position. Data were prospectively collected using the Keops DataBase (Smaio, Lyon, France), ODI, VAS and local safety. Evaluation of complications was performed by identifying the occurrence of any adverse event during the entire study follow-up. The relationship between complications and the medical device was analysed.

Surgical technique

The aim of the PSO was to recreate a segmental lordosis at the level of the theoretical apex of the patient's lumbar lordosis, generally performed at L4 or sometimes at L3. Nine patients were operated using an additional Smith-Petersen osteotomy. A mean of eight levels were included in the arthrodesis, with a maximum of 17 levels in cases of combined hyperthoracic kyphosis needing correction.

The eggshell technique [2] was used to decrease peroperative bleeding. In this series, vertebral osteotomies were performed at the lumbar and thoracic (one case) levels (Table 1). During this procedure, the dura mater was exposed on average 8–10 cm² before correction and 3–4 cm² after

Table 1 Description of spinal thoracolumbar osteotomy and arthrodesis

	Spinal osteotomy	Posterior corner (egg shell)	Combined with interpedicular (Smith-Petersen)
Patient (<i>n</i>)	26	17	9
One level [<i>n</i> (%)]	23 (88.5)	17 (74)	6 (26)
T4	1 (3.8)	1 (5.9)	0 (0)
L1	1 (3.8)	1 (5.9)	0 (0)
L2	1 (3.8)	1 (5.9)	0 (0)
L3	3 (11.5)	2 (11.8)	1 (11.1)
L4	17 (65.4)	12 (70.6)	5 (66.7)
Two levels [<i>n</i> (%)]	2 (7.7)	/	2 (22.2)
L2–L3 and L3–L4			
Three levels [<i>n</i> (%)]	1 (3.8)	/	1 (11.1)
L3–L5			
With arthrodesis cage [<i>n</i> (%)]	6 (23.1)	1 (5.9)	5 (55.6)
Without arthrodesis cage [<i>n</i> (%)]	20 (76.9)	16 (94.1)	4 (44.4)
Osteosynthesis material extent [<i>n</i> (%)]			
5 vertebrae	1 (3.8)	1 (5.9)	0 (0)
6 vertebrae	6 (23.1)	6 (35.3)	0 (0)
7 vertebrae	7 (26.9)	2 (11.8)	5 (55.6)
8 vertebrae	6 (23.1)	5 (29.4)	1 (11.1)
9 vertebrae	3 (11.5)	2 (11.8)	1 (11.1)
13 vertebrae	1 (3.8)	0 (0)	1 (11.1)
16 vertebrae	1 (3.8)	0 (0)	1 (11.1)
17 vertebrae	1 (3.8)	1 (5.9)	0 (0)

correction because of closure of the spinal canal, the dural sac being partially covered by the remaining adjacent posterior arch. RCM placement was performed after closing the osteotomy in order to completely cover the dura mater. The membrane acts as a barrier between a potential haematoma and protects the spinal cord from bone grafts.

COVA™ (Biom'Up, France) is a *Conformité Européenne* (CE)-marked, patented, cross-linked RCM indicated for preventing adhesions and for guided tissue healing to restore anatomical planes. In spinal surgery, the membrane acts as a natural barrier between the dura mater and the adjacent tissues for adhesiogenic interventions. The membrane was hydrated for ten to 15 minutes in sterile saline at room temperature prior to use, then placed on the dural sac. It can be cut, sutured or glued. The collagen membrane is resorbed in 13 weeks (internal preclinical data provided by manufacturer).

Assessment

All patients were followed up at six and 12 months. Pain and disability evaluation in terms of percentage of improvements were analysed from baseline data. Patients were categorised into four groups according to ODI improvement: >50 %, excellent results; 25–50 %, good; –25 to 24 %, unchanged; <–25 %, poor. Re-operations allowed us to evaluate the presence or not of dural adhesions, determine their incidence during the surgical

procedure according to a standard adhesions scale (0, none; 1, light; 2, mild; 3, severe), and ease of dissection was also noted, particularly regarding the dura mater.

Results

Demographic results

Twenty-six patients, 15 women (58 %) and 11 men (42 %), with a mean age of 57 years (min–max, 28–76), were consecutively operated, with RCM implantation (Table 2). Of the 26 patients, 73 % had a history of lower back pain with at least one previous surgery (spine fracture, discal hernia, recalibration of a narrow lumbar canal, previous short arthrodesis). Two patients were operated upon for a second osteotomy procedure at another level to complete sagittal balance correction. Twenty-four patients (92 %) were followed up, with a mean of 4.9 months±1.6. One patient was excluded from the study because the RCM was removed due to a nonrelated infection. One patient skipped the six month follow-up visit. All patients were followed up at a mean of 13.9±4.0 months. ODI and VAS clinical data were collected in the Keops database (Smaio, Lyon, France) at the pre-operative (*n*=21), six month (*n*=21) and 12-month visits (*n*=20).

Table 2 Patient demographic data ($n = 26$)

Characteristics		
Age \pm SD (range), years		57.3 \pm 14.2 [28 – 76]
Gender [n (%)]	Females	15 (58)
	Males	11 (42)
Professional activity [n (%)]	Active	17 (65.4)
	Inactive	9 (34.6)
Mean follow-up \pm SD, months	6-month	4.9 \pm 1.6
	12-month	13.9 \pm 4.4
History lumbar surgery [n (%)]		19 (73)

SD standard deviation

Global safety and efficacy

No fluid collection at the level of the collagen antiadhesion membrane or complication related to its use was reported. The presence of the RCM did not interfere with the ossification process. At the one year follow-up, all patients except one had a solid fusion assessed by computed tomography (CT) analysis. The re-operated patient who had pseudarthrosis became pain free, with good sagittal alignment, which is predictive of potential good fusion.

Per- and postoperative complications

No major intra-operative complication, such as spinal fluid leak, durotomy, coagulopathy with excessive bleeding or cardiovascular instability, was reported. Postoperative complications are described in Table 3.

Re-operations

Six re-operations were performed (23.1 %), four of which occurred during the immediate (15.4 %) and two in the late

Table 3 Postoperative complications

Overall complication profile [n (%)]	10 (38.5)
Early postoperative follow-up [n (%)]	
Superficial wound infection	3 (11.5)
Deep wound infection	1 (3.8)
Haematoma psoas muscle	1 (3.8)
Inguinal pain	2 (7.7)
Nonspecific digestive trouble ^a	
6-month follow-up [n (%)]	
Late infection	1 (3.8)
12-month follow-up [n (%)]	
Pseudarthrosis	1 (3.8)
Left sciatica	1 (3.8)

^a Nonspecific digestive troubles, including constipation and diarrhea

(7.7 %) follow-up. Their causes were not related to the use of the RCM or to the formation of adhesions. The early deep infection case had a revision at day 15, and the membrane was removed; there was no difficulty accessing the site (presence of light adhesions) or cleaning the dural sac. A membrane was not added in this case. For superficial wound infection cases, patients were treated by superficial debridement. All patients recovered completely after adaptive antibiotherapy, with no recurrence of infection at one year follow-up and with normalisation of all biological parameters.

Of the two late re-operations, one was due to late infection (107 days postoperatively) and one to pseudarthrosis two levels above the osteotomised vertebra. During these reinterventions, the ease of dissection and the formation of epidural adhesions were also assessed using a grading scale from 0 to 3. All adhesions were scored as grade 1, which corresponds to light adhesions, easily lysed with a spoonbill. No dural tear occurred during the procedure, and a new membrane was applied before closure (Figs. 2 and 3). For the three cases of superficial debridement, the presence of epidural adhesion could not be assessed.

Results

Oswestry Disability Index

Mean preoperative ODI score ($n=21$) was 49.4 % \pm 15.9, and half of the patients had a score better than 45 %. At six months, the ODI ($n=21$) was 38.6 % \pm 15.5, thus a mean reduction of 10.8 % and mean improvement of 21.9 % ($p<0.05$, significant, paired t test). At 12 months, the mean ODI ($n=20$) was 36.7 \pm 13.3, mean reduction was 12.7 % and functional improvement was 25.7 % ($p<0.05$, significant, paired t test) (Table 4).

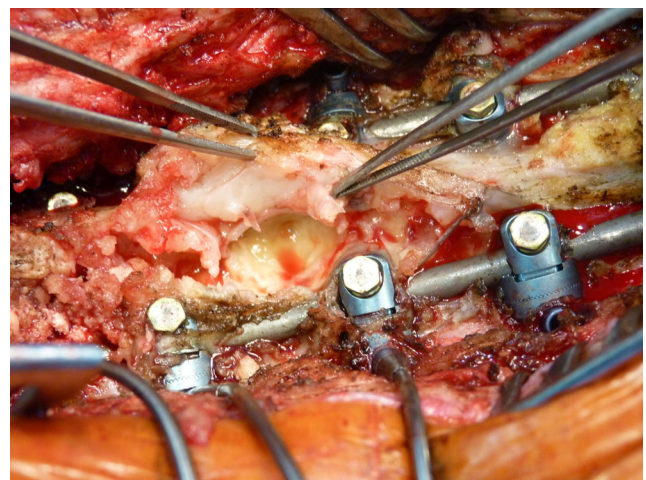


Fig. 2 Revision for pseudarthrosis: scar tissue covering the dura mater was easily detached without tearing

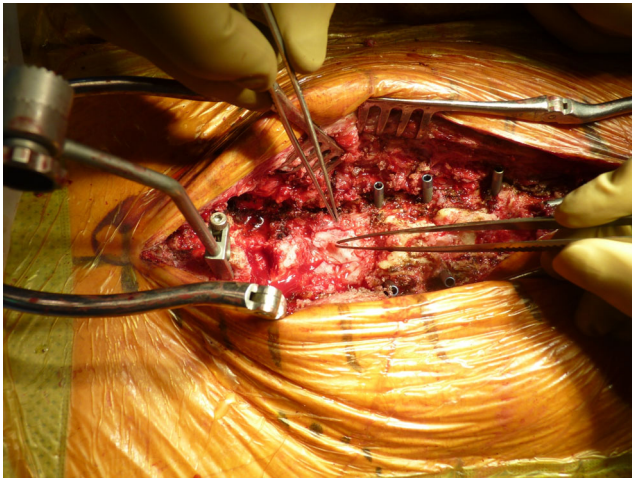


Fig. 3 After pseudarthrosis grafting, a new COVA membrane was used to again protect the dura mater

Patients were distributed into four groups according to variation of ODI score. At six and 12 months, respectively, 36.8 and 44.4 % of patients had good or excellent results, with an ODI improvement of at least 25 % (Table 5).

Pain

Preoperative mean VAS score for back pain was 7.4 ± 1.6 , which decreased to 5.0 ± 2.5 at 6 months and to 4.7 ± 2.0 ($p < 0.05$) at 12 months, corresponding to a significant reduction of 2.5 and 3.0 points, respectively, meaning an improvement of 33.1 and 39.9 % ($p < 0.05$; significant, paired t test) (Table 5). All patients experienced pre-operative leg pain before their surgery, with a mean VAS score of 6.7 ± 2.1 , which decreased to 3.8 ± 3.1 at six months and 3.4 ± 2.7 at 12 months, corresponding to a significant reduction of 2.9 and 3.3 points, respectively, and an improvement of 43.1 and 49.3 % ($p < 0.05$; significant, paired t test) (Table 6).

Discussion

Postoperative fibrosis is a consequence of surgical procedures. It can cause clinical complications, such as

recurrent radicular pain, due to formation of adhesions between tissues or to compression of organs and other anatomic structures by dense fibrotic scar [3]. In the case of lumbar spine surgery, there are numerous reports suggesting that fibrosis and adhesions may cause compression or tethering of the nerve root, which may lead to recurrent radicular pain and physical impairment. The presence of postoperative fibrosis is a consequence of fibrin formation in the epidural space surrounding the nerve root following intracanal surgery [4, 23]. Less invasive surgery for discectomy is thought to create less fibrous tissue and facilitate easier revision surgery. However, a retrospective study of patients reoperated for failed decompression by transforaminal lumbar interbody fusion (TLIF) compared with a primary TLIF procedure, showed that perineural fibrosis was present in both groups without significant differences and did not involve clinical outcomes [24]. This situation is different in cases of wide dural exposure, like lumbar osteotomies. Root ischaemia due to tethering may be an important contributing cause of radicular pain [5, 7–9, 25]. Failed back surgery syndrome (FBSS) comprises a set of postoperative spinal complications felt in the lower back and inferior limb and is reported at a rate of 5–20 % [26]. Causes are various, and among them, lumbosacral fibrosis is the most frequent [27]. Consequences induce uncomfortable situations and repeat surgery, as reported by Cheng with cases of spinal revision due to adhesions [28]. Moreover, 15–18 % of patients who undergo spine surgery are re-operated upon in the following five years [10], and revisions are mainly performed at the same location as the primary procedure [28].

This monocentric prospective clinical study investigated the safety and efficacy of a RCM, COVA™, used in lumbar vertebral osteotomy, a procedure at high risk of fibrous tissue development due to its extensive exposure of the dural sac. Complication rate is known to be high in this complex procedure. The meta-analysis of Dangelmajer et al. [29] shows a mean rate of 48.4 % using the open approach. This is a higher complication rate than that observed in our series (38.4 %). Moreover, among complications, no adverse effect related to the use of the RCM was reported. The most common reported

Table 4 Oswestry Disability Index score

	Mean ODI \pm SD % (range)	Decrease (unit)	Improvement (%)	<i>P</i> value
Pre-operative ($n=21$)	49.4 ± 15.9 (24 – 76)	/	/	
6-month ($n=21$)	38.6 ± 15.5 (8 – 68)	10.8	21.9	0.023*
12-month ($n=20$)	36.7 ± 13.3 (12 – 58)	12.7	25.7	0.009*

SD standard deviation

*Significant

Table 5 Patient improvement rate according to Oswestry Disability Index

	Low <-25 %	Unchanged ≥-25 to <25 %	Good ≥25 to <50 %	Excellent ≥50 %
6-month (n=21)	15.8 %	47.4 %	26.3 %	10.5 %
12-month (n=20)	16.7 %	38.9 %	27.8 %	16.7 %

complication at immediate follow-up was early postoperative infections. Infection is frequent in spine surgery, with a range from 0.3 to 20 % [30], especially in major spine surgery such as osteotomy [31], kyphosis or scoliosis [30]. In our study, early infections were superficial (suprafascial) or deep for 11.5 and 3.8 % of cases, respectively. Before osteotomy, all patients underwent multiple spine surgeries, which increase the risk of infection. The other risk factors for infected patients were smoking (3/5) and body mass index (BMI)>32 (2/5). No other severe complication, such as described by Mummaneni et al. [31], was reported, including epidural haematoma. Pain was also commonly reported during the follow-up, but all patients improved after surgery, and 23 (88.5 %) of 26 would recommend this procedure.

In this study, some clinical findings were investigated, providing information on the efficacy of RCM as an anti-adhesion barrier: functional disability, pain and surgical observations from re-operations. The ODI is one of the most commonly used specific questionnaires for evaluating the impacts of spinal disorder [32]. Although the ODI deliberately focuses on physical activities and not psychological consequences of acute or chronic pain, it remains a valid and vigorous measure of condition-specific disability [30]. The ODI at six and 12 months from pre-operative baseline shows a significant decrease in disability related to the pathology. In parallel, pain was also evaluated using the VAS, and significant decreases were recorded at both follow-up visits. These results show an improvement in physical and psychological conditions, which allows patients to recover normal activities, with a subsequent highly enhanced quality of life (QoL). Copay et al. [33] determined the minimum clinically important difference (MCID)

of ODI and VAS related to spinal surgical treatment. Based on these outcomes, we see a positive clinical impact of the osteotomy procedure and adhesion prevention strategy on patients' health and QoL. Arroategi [26] published a randomised comparative study evaluating a collagen antiadhesion device in spinal surgery and reported that at six, 12 and 24 months, pain was significantly reduced. Our study had no control group, and the pain scale used was not the same as Arroategi's study, but for the equivalent period, pain was significantly reduced.

Adhesion to soft tissue, such as veins, or to fragile structures is always a challenge when performing revision surgery [6]. For spine revision surgery, the challenge is double, as for anterior approaches, the surgeon must manage great vessels and the veins at the same time as dural adhesions; for posterior approaches, it is mainly dural adhesions that must be dealt with. Regardless, the problem is similar in both cases, being the risk of tearing fragile membranes: veins or dura mater. The use of an anti-adhesion barrier that provides more safety in the event of revision may decrease complications related to re-operation. It is difficult to report large series on such adhesions, as each case is individual and most reports are observational. Only on animal models can large series be reported [27]. In our series, the re-operation rate observed (23.1 %) is comparable with the re-operation rate reported in the literature (29.9 %) [29]. Among the causes of re-operations, none was related to the use of the RCM or to adhesion formation. In revision in which the membrane was exposed (early revision) and in the two in which the membrane was resorbed (late deep infection and pseudoarthrosis), RCM efficacy was estimated. In these cases, evaluation of fibrosis present in the operative site showed slight adhesion (grade 1) and facility to dissect and separate tissues. Beyond a period of three months, the

Table 6 Lower back and leg pain [visual analogue scale (VAS)]

	Mean VAS ± SD (range)	Decrease (unit)	Improvement (%)	P value
Lower back				
Pre-operative (n=21)	7.4±1.6 (3–10)	/	/	/
6-month (n=21)	5.0±2.5 (0–8)	2.5	33.1	0.0002*
12-month (n=20)	4.5±1.9 (1–8)	3.0	39.9	<0.0001*
Leg				
Pre-operative (n=21)	6.7±2.1 (0–10)	/	/	/
6-month (n=21)	3.8±3.1 (0–9)	2.9	43.1	0.001*
12-month (n=20)	3.4±2.7 (0–8)	3.3	49.3	0.0003*

SD standard deviation

*Significant

collagen antiadhesion membrane was completely resorbed, and all complications after this period were unrelated to fibrosis formation.

Conclusion

Several clinical trials have studied the safety and efficacy of antiadhesion devices but rarely on major spinal surgery such as vertebral osteotomy. Shih et al. [34] and Arroategui [26] demonstrated in their investigations the safety and efficacy of a collagen device used in spine surgery. Indeed, using an anti-adhesion device could result in lower re-operation rate, lower pain scores and lower adhesion formation.

Our clinical findings suggest a real benefit to using the RCM due to the absence of complications related to its use and its protective action on the dura mater, which is highlighted by the ease of dissection during re-operation. Improvement of ODI and VAS scores are more difficult to apply to use of the membrane, since other major parameters were modified to restore good clinical function.

In this prospective clinical study, the COVA membrane, indicated in preventing surgical adhesions and for guided tissue healing, showed good midterm tolerance and safety. Clinical findings observed during the follow-up confirm the benefit of using the collagen antiadhesion membrane following vertebral osteotomy. Re-operations confirmed much easier dissection and the absence of compressive fibrosis in contact with the dura mater.

References

- Le Huec JC, Roussouly P (2011) Sagittal spino-pelvic balance is a crucial analysis for normal and degenerative spine. *Eur Spine J* 20(Suppl 5):556–557
- Enercan M, Ozturk C, Kahraman S, Sarier M, Hamzaoglu A, Alanay A (2013) Osteotomies/spinal column resections in adult deformity. *Eur Spine J* 22(Suppl 2):S254–S264
- Ross JS, Robertson JT, Frederickson RC, Petrie JL, Obuchowski N, Modic MT, deTribonet N et al (1996) Association between peridural scar and recurrent radicular pain after lumbar discectomy: magnetic resonance evaluation. *ADCON-L European Study Group. Neurosurgery* 38:855–861
- Ido K, Urushidani H (2001) Fibrous adhesive entrapment of lumbosacral nerve roots as a cause of sciatica. *Spinal Cord* 39:267–273
- Cooper RG, Freemont AJ, Hoyland JA, Jenkins JP, West CG, Illingworth KJ, Jayson MI (1995) Herniated vertebral disc-associated periradicular fibrosis and vascular abnormalities occur without inflammatory cell infiltration. *Spine* 20:591–598
- Gerometta A, Rodriguez Olaverri JC, Bittan F (2012) Infection and revision strategies in total disc arthroplasty. *Int Orthop* 36:471–474
- Jayson MI (1989) Vascular damage, fibrosis, and chronic inflammation in mechanical back problems *Semin. Arthritis Rheum* 18:73–76
- Rydevik B, Brown MD, Lundborg G (1984) Pathoanatomy and pathophysiology of nerve root compression. *Spine* 9:7–15
- Rydevik B, Myers RR, Powell HC (1989) Pressure increases in the dorsal root ganglion after mechanical compression. *Spine* 14:574–576
- Malter AD, McNeney B, Loeser J, Deyo RA (1998) 5-year reoperation rates after different types of lumbar spine surgery. *Spine (Phila Pa 1976)* 23:814–820
- Abitbol JJ, Lincoln TL, Bl L, Amiel D, Akeson WH, Garfin SR (1994) Preventing postlaminectomy adhesion: a new experimental model. *Spine* 19:1809–1814
- Hinton JL, Warejcka DJ, Mei Y, McLendon RE, Laurencin C, Lucas PA, Robinson JS Jr (1995) Inhibition of epidural scar formation after lumbar laminectomy in the rat. *Spine* 20:564–570
- Songer MN, Rauschnig W, Carson EW, Pandit SM (1995) Analysis of peridural scar formation and its prevention after lumbar laminotomy and discectomy in dogs. *Spine* 20:571–580
- Jacobs R, McClain O, Neff J (1980) Control of postlaminectomy scar formation: an experimental and clinical study. *Spine* 5:223–229
- Zou X, Li H, Egund N, Lind M, Büniger C (2004) Inhibition of spinal fusion by use of a tissue ingrowth inhibitor. *Eur Spine J* 13:157–163
- Kitano T, Zerwekh JE, Edwards ML, Usui Y, Allen MD (1991) Viscous carboxymethylcellulose in the prevention of epidural scar formation. *Spine* 16:820–823
- Langenskjöld A, Kiviluoto O (1976) Prevention of epidural scar formation after operations on the lumbar spine by means of free fat transplants. *Clin Orthop Relat* 115:92–95
- Gill GG, Scheck M, Kelley ET, Rodrigo JJ (1985) Pedicle fat grafts for the prevention of scar in low-back surgery: a preliminary report on the first 92 cases. *Spine* 10:662–677
- Yong-Hing K, Reilly J, de Korompay V, Kirkaldy-Willis WH (1980) Prevention of nerve root adhesions after laminectomy. *Spine* 5:59–64
- MacKay MA, Fischgrund JS, Herkowitz HN, Kurz LT, Hecht B, Schwartz M (1995) The effect of interposition membrane on the outcome of lumbar laminectomy and discectomy. *Spine* 20:1793–1796
- Jensen TT, Asmussen K, Berg-Hansen EM, Lauritsen B, Manniche C, Vinterberg H, Jensen L, Kramhøft J (1996) First-time operation for lumbar disc herniation with or without free fat transplantation. Prospective triple-blind randomized study with reference to clinical factors and enhanced computed tomographic scan 1 year after operation. *Spine* 21:1072–1076
- Bernsmann K, Krämer J, Ziozios I, Wehmeier J, Wiese M (2001) Lumbar micro disc surgery with and without autologous fat graft : a prospective randomized trial evaluated with reference to clinical and social factors. *Arch Orthop Trauma Surg* 121:476–480
- Manchikanti L, Saini B, Singh V (2001) Spinal endoscopy and lysis of epidural adhesions in the management of chronic low back pain. *Pain Physician* 4:240–265
- Gillard DM, Corenman DS, Dorman GJ (2014) Failed less invasive lumbar spine surgery as a predictor of subsequent fusion outcomes. *Int Orthop* 38:811–815
- Howe JF, Loeser JD, Calvin WH (1977) Mechanosensitivity of dorsal root ganglion and chronically injured axons. A physiological basis for the radicular pain of nerve root compression. *Pain* 3:25–41
- Arroategi I (2011) Reduction of clinical symptoms after lumbar discectomy using Collagen Dural Matrix clinical trial. *World Spinal Column J* 2(1):7–11
- Gill GG, Sakovich L, Thompson E (1979) Pedicle fat grafts for the prevention of scar formation after laminectomy. An experimental study in dogs. *Spine* 4:176–186
- Cheng J, Wang H, Zheng W, Li C, Wang J, Zhang Z, Huang B, Zhou Y (2013) Reoperation after lumbar disc surgery in two hundred and seven patients. *Int Orthop* 37:1511–1517

29. Dangelmajer S, Zadnik P, Rodriguez S, Gokaslan ZL, Sciubba DM (2014) Minimally invasive spine surgery for adult degenerative lumbar scoliosis. *Neurosurg Focus* 36(5):E7
30. Smith JS, Shaffrey CI, Sansur CA et al (2011) Rates of infection after spine surgery based on 108,419 procedures: a report from the Scoliosis Research Society Morbidity and Mortality Committee. *Spine* 36:556–563
31. Mummaneni PV, Dhall SS, Ondra SL, Mummaneni VP, Berven S (2008) Pedicle subtraction osteotomy. *Neurosurgery* 63:171–176
32. Fairbank J, Couper J, Davies J, O'Brien JP (1980) The Oswestry low back pain questionnaire. *Physiotherapy* 66:271–273
33. Copay AG, Glassman SD, Subach BR, Berven S, Schuler TC, Carreon LY (2008) Minimum clinically important difference in lumbar spine surgery patients: a choice of methods using the Oswestry Disability Index, Medical Outcomes Study questionnaire Short Form 36, and pain scales. *Spine J* 8:968–974
34. Shih HN, Fang JF, Chen JH, Yang CL, Chen YH, Sung TH, Shih LY (2004) Reduction in experimental peridural adhesion with the use of a crosslinked hyaluronate/ collagen membrane. *J Biomed Mater Res B Appl Biomater* 71B:421–428